

## Anatomical variation of the azygos vein in human cadavers

*Samy Ismail Ahmed Mustafa<sup>1</sup>, Tahir Osman Ali<sup>2</sup>, and Aamir Ali Ahmed<sup>3</sup>*

<sup>1</sup>Department of Anatomy, Faculty of Medicine, Najran University, Saudi Arabia

<sup>2</sup>Faculty of Graduate Studies & Scientific Research, National Ribat University, Sudan

<sup>3</sup>Department of Physiology, Faculty of Medicine, Najran University, Saudi Arabia

Copyright © 2016 ISSR Journals. This is an open access article distributed under the **Creative Commons Attribution License**, which permits unrestricted use, distribution, and reproduction in any medium, provided the original work is properly cited.

**ABSTRACT:** Thirty embalmed adult human cadavers irrespective of age, sex and cause of death, were selected for this study over a period of one year to determine the azygos vein formation and drainage patterns. This study revealed four varieties regarding azygos vein formation. In twenty two cases (73.3%), the azygos vein formed by the confluence of the right subcostal and right ascending lumbar vein. It formed by the right subcostal vein with a contribution from the inferior vena cava (IVC) in three cases (10.0%) while, it formed by the right and left subcostal veins in three cases (10.0%) and in two cases (6.7%) formed by the right subcostal vein only. Moreover, in twenty three cases (76.67%), the azygos vein showed usual course and tributaries. Five cases (16.67%) revealed midline azygos vein with independent left lower eight posterior intercostal and subcostal veins. One case (3.33%) showed (H) shape azygos system. Independent double azygos veins were found in one case (3.33%). Based on the results, the azygos vein can take different developmental variations. Such variations are important in mediastinal surgery, imperative for reporting radiologists and have clinical importance. Variations in the formation and drainage pattern of the azygos vein are not clearly described in the literature. In this study the possible causes of these types of variations are discussed in view of the embryological development.

**KEYWORDS:** Azygos vein, Surgical, Embryological, Embalmed, Variations, Anatomy.

### 1 INTRODUCTION

The azygos vein is a vascular structure of extreme importance that drains blood from the posterior walls of the thorax and abdomen. It is often formed by the union of the right ascending lumbar vein and the right subcostal vein anterior to the twelfth thoracic vertebral body. It passes through the aortic opening of the diaphragm and ascends in the posterior mediastinum on the right side of the thoracic aorta to the level of the fifth thoracic vertebra. Here it arches forward above the root of the right lung to empty into the posterior surface of the superior vena cava<sup>[1]</sup>. Therefore, it acts as a collateral circulation and an alternative pathway in both directions in cases of superior vena cava occlusion<sup>[2]</sup>.

The azygos vein has numerous tributaries, including the eight lower right intercostal veins, the right superior intercostal vein, the superior and inferior hemiazygos veins, and numerous mediastinal veins<sup>[3]</sup>.

During its early development, azygos vein may exhibits many variations that may affect its normal origin, course, termination as well as normal drainage<sup>[4]</sup>.

The azygos vein variations may easily be confused with vascular diseases and other abnormalities. It is important to keep these types of variations and their embryological basis in mind while performing the posterior mediastinal computed tomography and magnetic resonance imaging, surgical operations of large vessels to minimize unnecessary bleeding from these veins and decrease the risk of their injuries<sup>[5], [6], [7]</sup>.

## 2 MATERIAL AND METHOD

The present study was carried out in the department of anatomy, faculty of medicine, Ribat University. A total number of 30 embalmed and fixed in 10% formaldehyde adult human cadavers irrespective of age, sex and cause of death, used for undergraduate dissection were selected for this study over a period of one year.

Dissection was performed to expose the posterior mediastinum and the adjoining retroperitoneal structures of the posterior abdominal wall, in order to identify and observe the formation and course as well as drainage pattern variations of the azygos vein, and photographs were taken for unusual cases.

## 3 RESULT

### 3.1 THE AZYGOS VEIN FORMATION

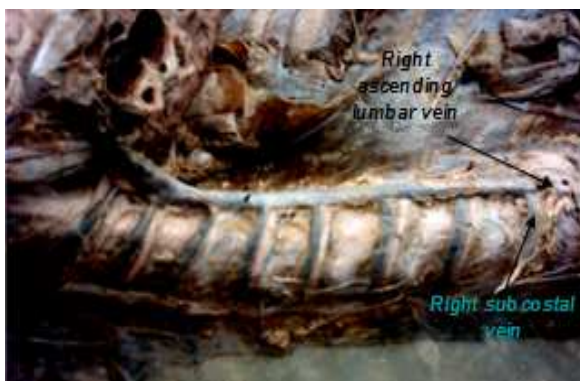In the present study the azygos vein showed variable formation, having one or two roots.

The most frequent formation was formed by the confluence of the right subcostal and right ascending lumbar vein in twenty two cases (73.3%) (Fig.1); by the right subcostal vein with a contribution from the inferior vena cava (IVC) in three cases (10.0%) (Fig.2); by the right and left subcostal veins with absence of the hemiazygos veins and independent left lower eight posterior intercostal in three cases (10.0%) (Fig. 3) and in two cases (6.7%) (Fig. 4) formed by the right subcostal vein only.

### 3.2 THE AZYGOS VEIN COURSE AND TRIBUTARIES

The present study demonstrated that: in twenty three cases ( 76.67%) the azygos vein showed usual course and tributaries including the eight lower right intercostal veins, the right superior intercostal vein, the accessory hemiazygos vein at the level of seventh thoracic vertebra and hemiazygos vein the level of eighth thoracic vertebra , and numerous mediastinal veins.

Five cases (16.67%) revealed midline azygos vein with independent left lower eight posterior intercostal veins (Fig. 3).One case (3.33%) (Fig.6) showed (H) shape azygos system in which, the superior and inferior hemiazygos veins joined each other and connected to the azygos vein by one transvertebral connection at the level of ninth thoracic vertebra. While, independent parallel double azygos veins being anterior and lateral to the vertebral column was found in one case (3.33%) (Fig.7).



**Figure (1):** shows the azygos vein formed by(Rt) subcostal & (Rt) ascending lumbar veins.



**Figure (2):** shows the azygos vein formed by (Rt) subcostal vein and continuation from inferior vena cava (IVC).

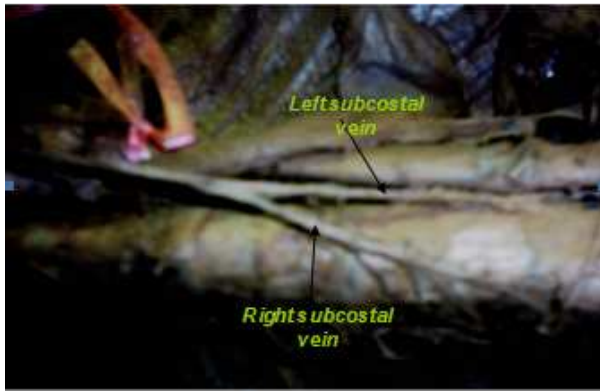


Figure (3): shows the azygos vein formed by (Rt) & (Lt) subcostal veins.

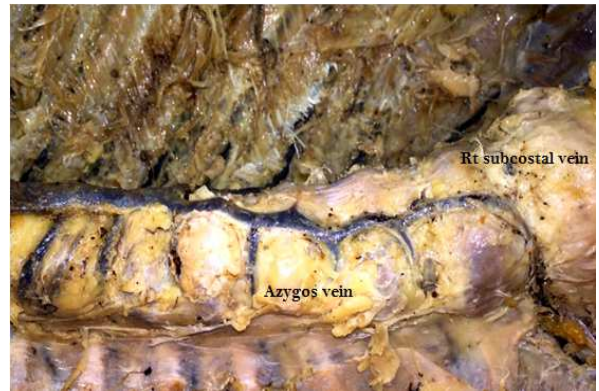


Figure (4): shows the azygos vein formed By (Rt) subcostal only.



Figure (5): midline azygos vein with independent left lower eight posterior intercostal veins.

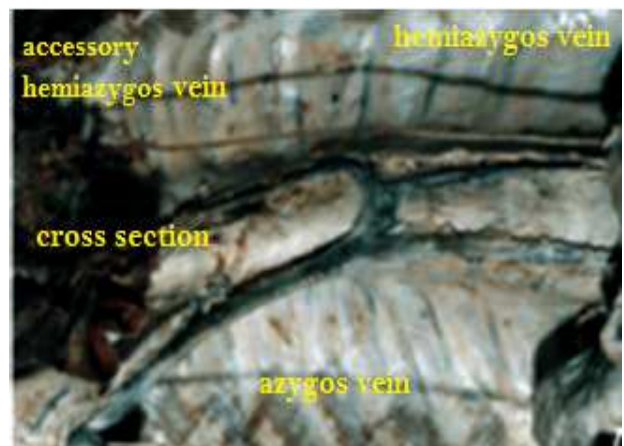

Figure (6): shows (H) azygos system which azygos vein drain the hemiazygos veins by one transvertebral connection at the level of ninth thoracic vertebra.



Figure (7): shows independent double azygos veins.

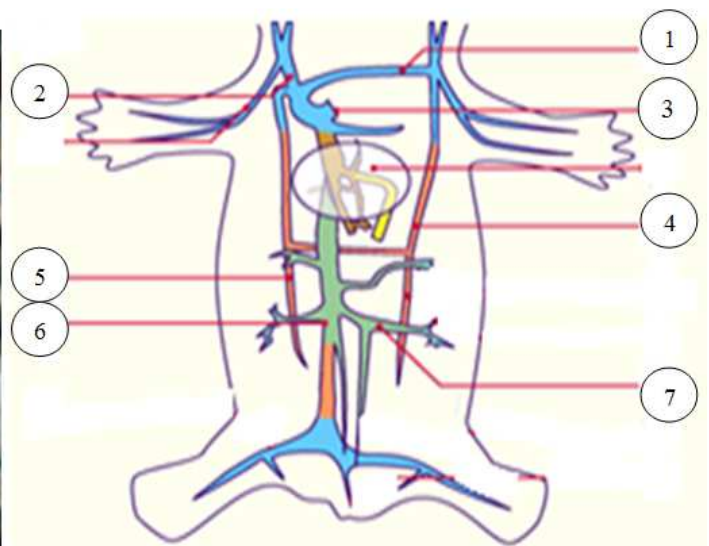


Figure (8): shows the embryological basis of the azygos system of veins. 1. Lt. brachiocephalic vein 2. Rt. Brachiocephalic vein 3. sinus venosus 4. Lt. supracardinal vein 5. Rt. supracardinal 6. Rt. subcardinal vein 7. Lt. renal vein.

## 4 DISCUSSION

Identification of azygos vein variations in its origin, course and tributaries are vitally important in surgical, radiological and clinical procedures. These variations are generally explained on the basis of its embryological development. Development of the azygos vein depends primarily on various modifications during the development of the cardinal veins which appear in the third week<sup>[8]</sup>. Therefore, azygos vein can show varieties in its formation course and drainage pattern. However, it maintains a connection between venacaval and portocaval systems and forms an important route of collateral circulation in case of venacaval occlusion such as in portal hypertension<sup>[9]</sup>.

Although the azygos system development is somewhat controversial, the azygos vein is often formed by the right supracardinal vein and the terminal part of right posterior cardinal vein. Whereas, the hemiazygos veins are formed by left supracardinal vein. The connections between the azygos and hemiazygos veins are formed by the persistence of the embryological anastomosis between right and left supracardinal veins and the right subcardinal vein (Fig. 8) which forms the renal segment of the inferior vena cava<sup>[7], [10]</sup>.

In the present study, the origin of the azygos vein was mainly found to be formed by the combination of the right subcostal and right ascending lumbar vein in twenty two cases (73.3%), which represent the usual pattern and the normal development of cardinal veins. Described in the literature<sup>[3], [10], [11]</sup>

In (16.7%) of this study cases, the azygos vein was formed by the right subcostal vein with a contribution from the inferior vena cava which is consistent with the recent study by Suot Keskin *et al*<sup>[2]</sup>.

The contribution OF IVC could be explained by the persistence of embryological anastomosis between the right supracardinal (intermediate segment) and right subcardinal veins<sup>[12], [13]</sup>.

Formation of azygos vein by the right and left subcostal veins was found in three cases (10.0%) with independent left lower eight posterior intercostal veins. While in two cases (6.7.0%) it was only formed by the right subcostal vein with independent left lower eight posterior intercostal veins. These two findings were also reported by<sup>[2]</sup>. Such varieties might be due to the undeveloped or atrophied abdominal part of the right supracardinal vein which form the right ascending lumbar vein with the absence of the left supracardinal vein which form the hemiazygos veins<sup>[14]</sup>.

Regarding variations in the course and drainage pattern, in (76.67%) of The present study cases, the azygos vein showed usual course and tributaries including the eight lower right intercostal veins, the right superior intercostal vein, the accessory hemiazygos vein at the level of seventh thoracic vertebra and hemiazygos vein the level of eighth thoracic vertebra, and numerous mediastinal veins<sup>[1]</sup>. This indicates the normal development of the cardinal veins.

The midline azygos vein with independent left lower eight posterior intercostal veins which found in five of study cases (16.67%), could be due to the undeveloped left supracardinal vein. Whereas, the (H) shape azygos veins embryologically referred to persistence of the left supracardinal vein with one subcentral anastomosis<sup>[11]</sup>.

The separate azygos veins lying parallel to each other seen in (3.33%) of cases, might be due to the persistence of complete left supracardinal vein with degenerated subcentral anastomosis<sup>[7], [15]</sup>.

## 5 CONCLUSION

Alterations in the various developmental modifications of azygos lines (the cardinal veins) of veins. affect the normal origin, or course, or the drainage pattern of the azygos veins.

Bearing in mind, the right subcostal vein was substantial in the formation of the azygos vein in all cases of this study (100%).

As azygos system of veins constitutes a collateral circulation and an alternative pathway in the case of superior vena cava obstructions, identification of its anatomical variations is essential for radiographic imaging and avoiding posterior mediastinum surgical complications for optimal patients outcome.

## REFERENCES

- [1] Richard S. Snell. Clinical anatomy. Lippincott Williams and Wilkins; 7th dEdition Philadelphia, Pennsylvania, 2004.
- [2] ALVES, E. C.; PORCIÚNCULA JUNIOR, R. W.; MONTE BISPO, R. F.; DE SOUSA-RODRIGUES, C. F. & DA ROCHA, A. C. Formation of the azygos vein. Int. J. Morphol., vol. 29, no 1, pp.140-143, 2011.

- [3] Moore, K. & Dalley, A.S. *Anatomia Orientada para a Clínica*. 4a ed. Rio de Janeiro, Guanabara Koogan, 2001.
- [4] P. L. Williams, L. H. Bannister, and M.M. Berry, *Gray's Anatomy*, 38th British edition, Churchill Livingstone, New York, NY, USA, 1995.
- [5] Y. Srinivasa Rao, b Arindom Banerjee. Anatomical variations of the azygos venous system. *Int J Biol Med Res.*; vol. 5, no. 4, pp. 4535-4538, 2014.
- [6] J. Pyrzowski, J.H. Spodnik, A. Lewicka, A. Popławska, S. Wójcik. A case of multiple abnormalities of the azygos venous system: a preaortic interazygos vein. *Folia Morphol*, Vol. 66, No. 4, pp. 353–355, 2007.
- [7] Narayanan.G. , Aruna. S , Balaji T.K., Kannan.G., Venkateshgobi.V. A Study on Azygos System of Veins and Venous Aneurysm. *Journal of Nursing and Health Science (IOSR-JNHS)*, Vol. 2, no 2, pp.1940 -2320, 2013.
- [8] Standring S. *Gray's Anatomy. The Anatomical Basis of Clinical Practice*. 39th ed. Churchill Livingstone, pp1025-1027, 1045-1050, 2005.
- [9] Elzbieta Krakowiak-Sarnowska et al. Variability of the azygos vein system in human fetuses. *Via medica J*, vol. 62, no. 4, pp. 427 – 430, 2003.
- [10] Sadler T W. *Development of Cardiovascular system. Langman's Medical Embryology*. 10th ed. Philadelphia, Lippincott Williams & Wilkins, 12:187-188, 2006.
- [11] T. KUTOGLU1), M. TURUT1), N. KOCABIYIK2), H. OZAN2), M. YILDIRIM3). Anatomical analysis of azygos vein system in human cadavers *Rom J Morphol Embryol*, vol. 53, no. 4, pp. 1051–1056, 2012.
- [12] Suat Keskin. Angiography of Azygos Continuation of Inferior Vena Cava with Polysplenia. *Eur J Gen Med*; vol. 10, no.1, pp. 39-41, 2013.
- [13] Gaynor JW, Weinberg PM, Spray TL, *Congenital heart Surgery Nomenclature and Database Project: systemic venous anomalies*, *Ann Thorac Surg*, vol. 69, (3 Suppl 1), pp. 70–76, 2000.
- [14] Necdet Kocabýýk, Tunç Kutođlu, Soner Albay, Býlent Yalçýn, Hasan Ozan . Azygos vein system abnormality: case report. *Gýlhane Týp Dergisi*; vol. 48, pp.180-182, 2006.
- [15] Constantin B. Marcu, Aernout M. Beek and albert C. Van Rossum. Unusual variation in upper body venous anatomy found with cardiovascular MRI. *Canadian Medical Association Journal*, vol. 175, no. 1, pp. 15039, 2006.