

Ovarian metastasis of the breast cancer: A Case Report

Abdellahi Ibrahim, Ali Osman, Farid Kassidi, Abdellah Babahabib, Jaouad Kouach, Driss Moussaoui, and Mohammed Dehayni

Service de gynécologie-obstétrique, Hôpital Militaire d'Instruction Mohamed V, Rabat, Morocco

Copyright © 2016 ISSR Journals. This is an open access article distributed under the **Creative Commons Attribution License**, which permits unrestricted use, distribution, and reproduction in any medium, provided the original work is properly cited.

ABSTRACT: Ovaries are a frequent site of metastasis of the breast cancer. The annexial metastases of breast cancer often present as a challenge for diagnosis and therapeutic. Distinction between ovarian metastasis and primary ovarian cancer may sometimes be difficult. The surgical resection tends to increase survival a surgical option should consist of at least bilateral oophorectomy, even when the contralateral ovary appears to be normal. We present the case of a 36-year-old female, followed by breast cancer since 2011 stage 1 initially (T1N1Mx), who underwent Patey (infiltrating ductal carcinoma) followed by radiotherapy and chemotherapy, hormone therapy, four years later the patient complained of abdominal distention, abdominal ultrasound showed ovarian mass then open laparoscopy was done, left adnexectomy was realized and finally histological diagnosis revealed Ovarian metastasis of the breast cancer.

KEYWORDS: Breast cancer; ovarian metastasis; Treatment.

INTRODUCTION

Breast cancer is the most common cancer in women in developed nations while Ovarian cancer is the most aggressive gynecological malignancy, the most frequent and best known metastatic sites of breast carcinoma are the bone, the liver and the lungs, while the ovary is a rare [3,12]. Most breast cancer deaths are related to distant metastases, the division of breast cancer into histologic subtypes (ductal, lobular, etc) and molecular subtypes (estrogen receptor positive/negative [ER+/-] and human epidermal growth factor receptor 2 [Her2+/-] is known to have significant prognostic and predictive value [2].

CASE PRESENTATION

A 36-year-old female Gravida 4 and 1,63 in height, weighing 56 Kg, without past history of familial neoplastic diseases, followed by breast cancer since 2011 stage 1 initially (T1N1Mx), infiltrating ductal carcinoma.

The patient underwent Patey's type modified radical mastectomy (MRM), followed by radiotherapy and chemotherapy, hormone therapy with regular follow up.

Four years later, the patient complained of abdominal pain with distention.

Abdominal ultrasound showed little peritoneal effusion associated left ovarian mass about 5x6 centimeters, abdominal and pelvic Computed tomographic scans show Peritoneal effusions with cystic and solid components intraperitoneal mass at left side of uterus measured 7x5 centimeters depend left ovary [figures 1,2]. Multidisciplinary decision was made laparoscopy, then open laparoscopy was done; the exploration showed solid white budding left ovarian mass of the 5x4 centimeters, exploration of the two fallopian tubes and, right ovary was normal. The biopsy of all the: peritoneal fluid, omentum, right ovary and endometrial biopsy was normal. Finally left adnexectomy was performed. The results of anatomic pathology confirmed: Ovarian metastasis of the breast cancer

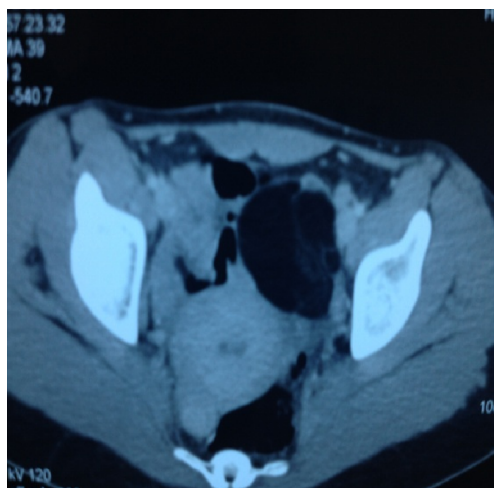


Figure 1

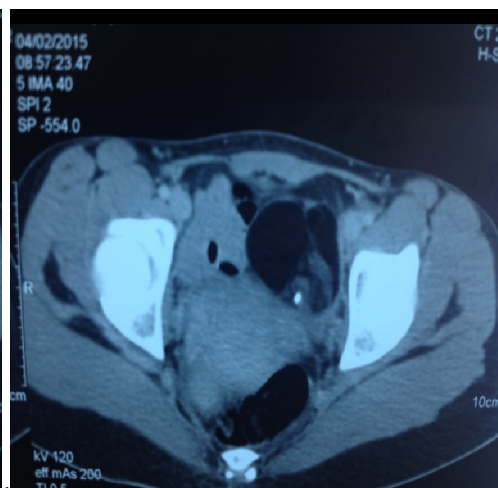

Figure 2

The two figures show cystic and solid left ovarian masses

DISCUSSION

Metastatic tumors of the ovary comprise a significant group of ovarian neoplasms, not only because of their incidence rate, but also because of diagnostic difficulties occurring when tumors histopathologically similar to primary ovarian neoplasms give metastases to the ovary [15]. Ovarian metastases count however for 5, 2 in 10 % of all the ovarian neoplasia and mammary origin is found in 21, 7 in 54, 2 % [3, 4].

Various authors have reported that the actual incidence of BRCA 1 mutations in patients with both breast and ovarian cancer is over 50% [6]. The average age of the patients during the diagnosis of ovarian metastasis is situated in the first half of about fifty, the interval separating the diagnosis of the primitive cancer of that of the ovarian metastasis is generally longer for the breast cancer than for that of different others primitive [4,6]. In our case the patient presented symptoms like abdominal pain and distension while imagery shown right ovarian mass four years since diagnosis of breast cancer

The macroscopic aspect of the metastatic ovary is generally that of a solid tumor and ovarian metastases in particular of mammary origin are usually small-sized [4].

The histological study of the primitive mammary carcinomas, the carcinomas canalaire is a superior compared with carcinomas lobulaires [4,7]. Tumors can spread to the ovary by several pathways, such as direct spread, transcoelomic dissemination, hematogeneous spread, and lymphatic spread ,however, there are many cases with mixed metastatic pathways, because the original cancers are detected at advanced stage[13].

All breast cancers were diagnosed before ovarian metastases [15]. The discovery of a suspect annexielle mass at a patient presenting a history of breast cancer raises the following problem: it is about a primitive ovarian neoplasia or about a metastasis of the breast cancer? [3]. Even if the annexielles metastases show a smaller size and are more often fleshy than primitive ovarian which have more frequently a mixed nature and a polykystique aspect, the criteria of imaging (ultrasound, magnetic resonance and scanner) do not allow us to differentiate them [2]. The bilaterality of the ovarian lesion, the presence of a peritoneal carcinomatosis, the preoperative dosage of Cancer Antigen 125 (CA-125) do not show any difference significant ? The dosage of the carcinoembryonic antigen (CEA) is a higher in case of annexielle metastasis, but is also raised in about 20 % of the ovarian primitive cancers [3].

During the discovery of an annexielle mass at a patient having a history of breast cancer, the laparoscopy will allow the obtaining of takings necessary biopsy for histological diagnosis [6], This way at first surgical could be also proposed for the resection of metastatic lesion presenting a limited extension. [3, 4, 6]. The residual tumoral volume after surgery is the only prognostic factor found in the literature, a survival in five years of 16 % when this residual tumoral volume is lower than 2 cm while it passes in 3 % when the residual tumoral volume is superior to 2 cm [4].

CONCLUSION

The annexielles metastases of a breast cancer are often the appearance of a metastatic at a patient having a past history known for breast cancer but can more rarely can be the initial demonstration appearance. The ultrasound remains the images of examination of choice in the presence of clinical signs which can direct to an ovarian tumor. Also, the laparoscopy seems to be the way of exploration favored to establish the histological diagnosis and estimate the respectability of the lesion.

REFERENCES

- [1] Mhaweche-Fauceglia P, Kay B, Li CJ, Lin YG. Metastatic ovarian papillary serous carcinoma to the breast: Diagnosis and pitfalls. *Gynecol Oncol Case Rep.* 2013 Jan 4;4:35-7.
- [2] St Romain P1, Madan R, Tawfik OW, Damjanov I, Fan F. Organotropism and prognostic marker discordance in distant metastases of breast carcinoma: fact or fiction? *Aclicinopathologic analysisHum Pathol.* 2012 Mar;43(3):398-404.
- [3] Dubois N1, Willems T, Myant N. [Ovarian metastasis of breast cancer: a case report. Role of cytoreductive surgery]. [Article in French]. *J Gynecol Obstet Biol Reprod (Paris).* 2009 May;38(3):242-5.
- [4] Perrotin F1, Marret H, Bouquin R, Fischer-Perrotin N, Lansac J, Body G. [Incidence, diagnosis and prognosis of ovarian metastasis in breast cancer]. [Article in French]. *Gynecol Obstet Fertil.* 2001 Apr;29(4):308-15.
- [5] Balaji R1, Ramachandran K, Anila KR. Ovarian carcinoma metastasis to the breast and imaging features with histopathologic correlation: a case reportand review of the literature. *Clin Breast Cancer.* 2009 Aug;9(3):196-8.
- [6] Tserkezoglou A1, Kontou S, Hadjieleftheriou G, Apostolikas N, Vassilomanolakis M, Sikiotis K, Salamalekis E, Tseke P, Magiakos G. Primary and metastatic ovarian cancer in patients with prior breast carcinoma. Pre-operative markers andtreatment results. *Anticancer Res.* 2006 May-Jun;26(3B):2339-44.
- [7] Bigorie V1, Morice P, Duvillard P, Antoine M, Cortez A, Flejou JF, Uzan S, Darai E, Barranger E. Ovarian metastases from breast cancer: report of 29 cases. *Cancer.* 2010 Feb 15;116(4):799-804.
- [8] BAYKAL C , TULUNAY G, ÖZFUTTU A , JACOBS J , A MEIN C ,KÜÇÜKAL T , AYHAN A. BREAST AND OVARIAN CARCINOMA IN THE SAME PATIENT, METASTASIS OR DUAL PRIMARIES? *Turkish Journal of Cancer* Volume 37, No.1, 2007.
- [9] Ogawa H , Hata T , Uemura M , Nishimura J, Hayashi T, Mizushima T , Doki Y , Mori M and Yamamoto H. Two Cases of Synchronous Metastasis of Colon Cancer to the Ovary. *Ogawa et al., General Med* 2013, 1:4 <http://dx.doi.org/10.4172/2327-5146.1000123>.
- [10] Losito NS1, Scaffa C, Cantile M, Botti G, Costanzo R, Manna A, Franco R, Greggi S. Lung cancer diagnosis on ovary mass: a case report. *J Ovarian Res.* 2013 May 10;6(1):34. doi: 10.1186/1757-2215-6-34.
- [11] Nakamura Y1, Hiramatsu A2, Koyama T2, Oyama Y2, Tanaka A3, Honma K4. A Krukenberg Tumor froman Occult Intramucosal Gastric Carcinoma Identified during an Autopsy. *Case Rep Oncol Med.* 2014;2014:797429.
- [12] Van Calster B1, Van Hoorde K2, Valentin L3, Testa AC4, Fischerova D5, Van Holsbeke C6, Savelli L7, Franchi D8, Epstein E9, Kaijser J10, Van Belle V2,Czekierdowski A11, Guerriero S12, Fruscio R13, Lanzani C14, Scala F15, Bourne T16, Timmerman D10; International Ovarian Tumour Analysis Group Evaluating the risk of ovarian cancer before surgery using the ADNEX model to differentiate between benign, borderline, early and advanced stage invasive, and secondary metastatic tumours: prospective multicentrediagnostic study. *BMJ.* 2014 Oct 15;349:g5920.
- [13] Yamanishi Y1, Koshiyama M, Ohnaka M, Ueda M, Ukita S, Hishikawa K, Nagura M, Kim T, Hirose M, Ozasa H, Pathways of metastases from primary organs to the ovaries. *Obstet Gynecol Int.* 2011;2011:612817.
- [14] Dionigi A1, Facco C, Tibiletti MG, Bernasconi B, Riva C, Capella COvarian metastases from colorectal carcinoma. Clinicopathologic profile, immunophenotype, and karyotypeanalysis. *Am J Clin Pathol.* 2000 Jul;114(1):111-22.
- [15] Perucchini D1, Caduff R, Schär G, Fink D, Köchli OR[Ovarian metastasis of extragenital tumors at the Zurich University Gynecologic Clinic 1978-1990]. [Article in German] *Geburtshilfe Frauenheilkd.* 1996 Jul;56(7):351-6